

Anatomy Review: Skeletal Muscle Tissue

Graphics are used with permission of:
adam.com (<http://www.adam.com/>)
Benjamin Cummings Publishing Co (<http://www.awl.com/bc>)

Page 1. Introduction

- Skeletal muscle cells have unique characteristics which allow for body movement.

Page 2. Goals

- To compare and contrast smooth muscle cells, cardiac muscle cells, and skeletal muscle cells.
- To review the anatomy of the skeletal muscle.
- To examine the connective tissue associated with the skeletal muscle.
- To review the intracellular organization of the skeletal muscle cell.

Page 3. Comparison of Skeletal, Cardiac and Smooth Muscle Cells

Skeletal Muscle Cell:


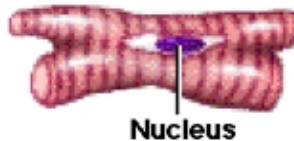
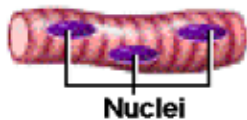
Elongated Cells
Multiple Peripheral Nuclei
Visible Striations
Voluntary

Cardiac Muscle:

Branching Cells
Single Central Nucleus
Visible Striations
Involuntary

Smooth Muscle Cell:

Spindle-Shaped Cell
Single Central Nucleus
Lack Visible Striations
Involuntary



** Now is a good time to go to quiz question 1:

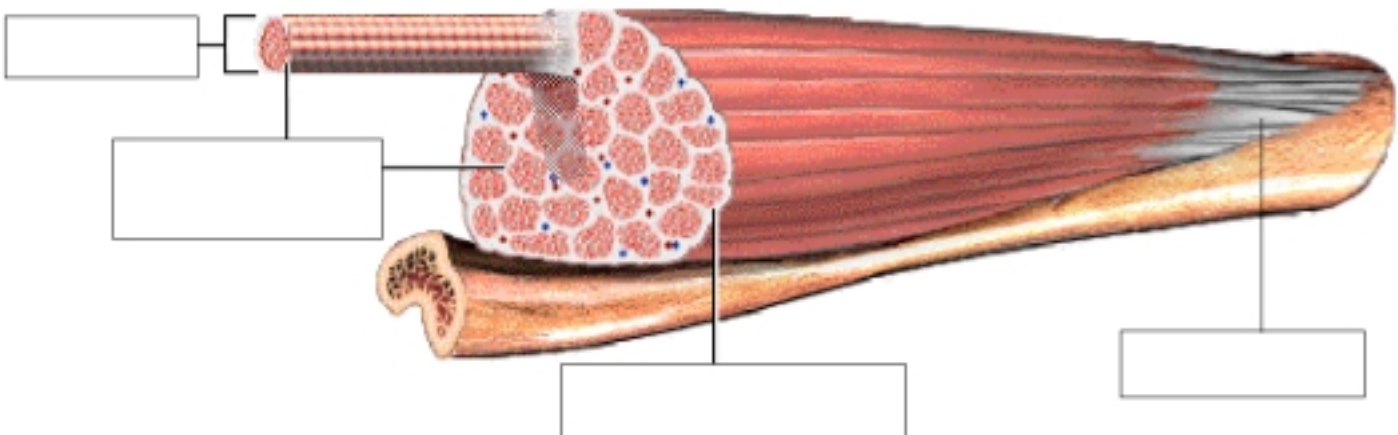
- Click the Quiz button on the left side of the screen.
- After answering question 1, click the Back to Topic button on the left side of the screen.
- To get back to where you left off, click on the scrolling page list at the top of the screen and choose "4. Whole Skeletal Muscle".

Page 4. Whole Skeletal Muscle

- Skeletal muscles attach to bones via tendons.

Page 5. Internal Structure of a Skeletal Muscle

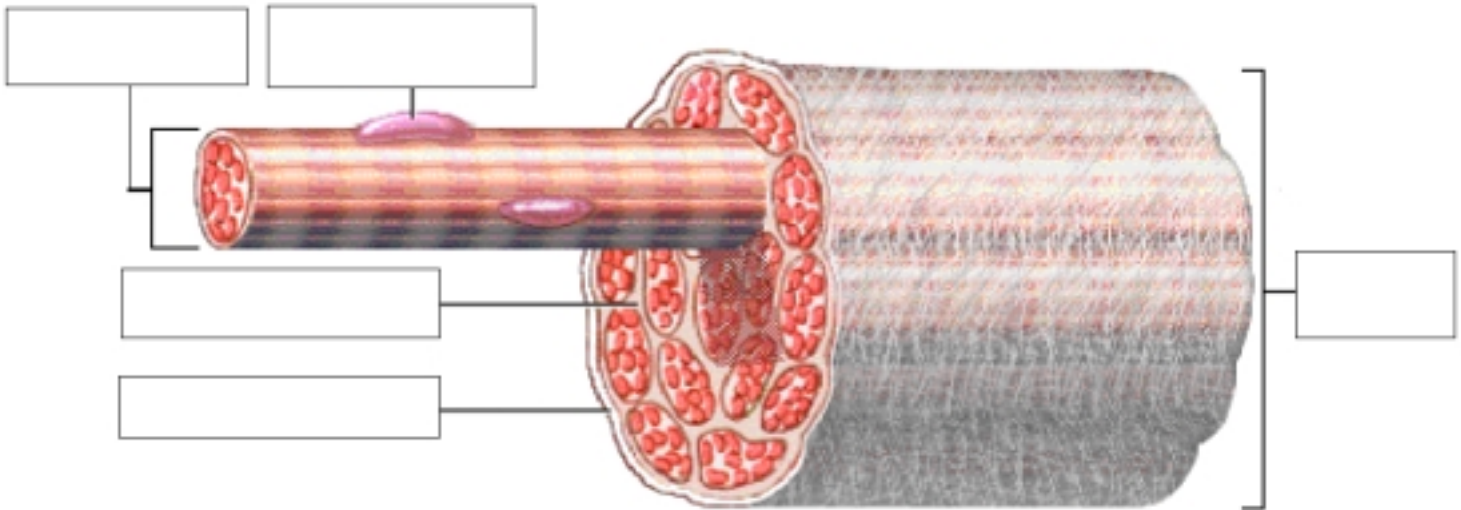
- Skeletal muscles are composed of connective tissue and contractile cells.
- The connective tissues surrounding the entire muscle is the epimysium. Bundles of muscle cells are called fascicles. The connective tissues surrounding the fascicles is called perimysium.
- Label this diagram:



Page 6. Internal Structure of a Fascicle

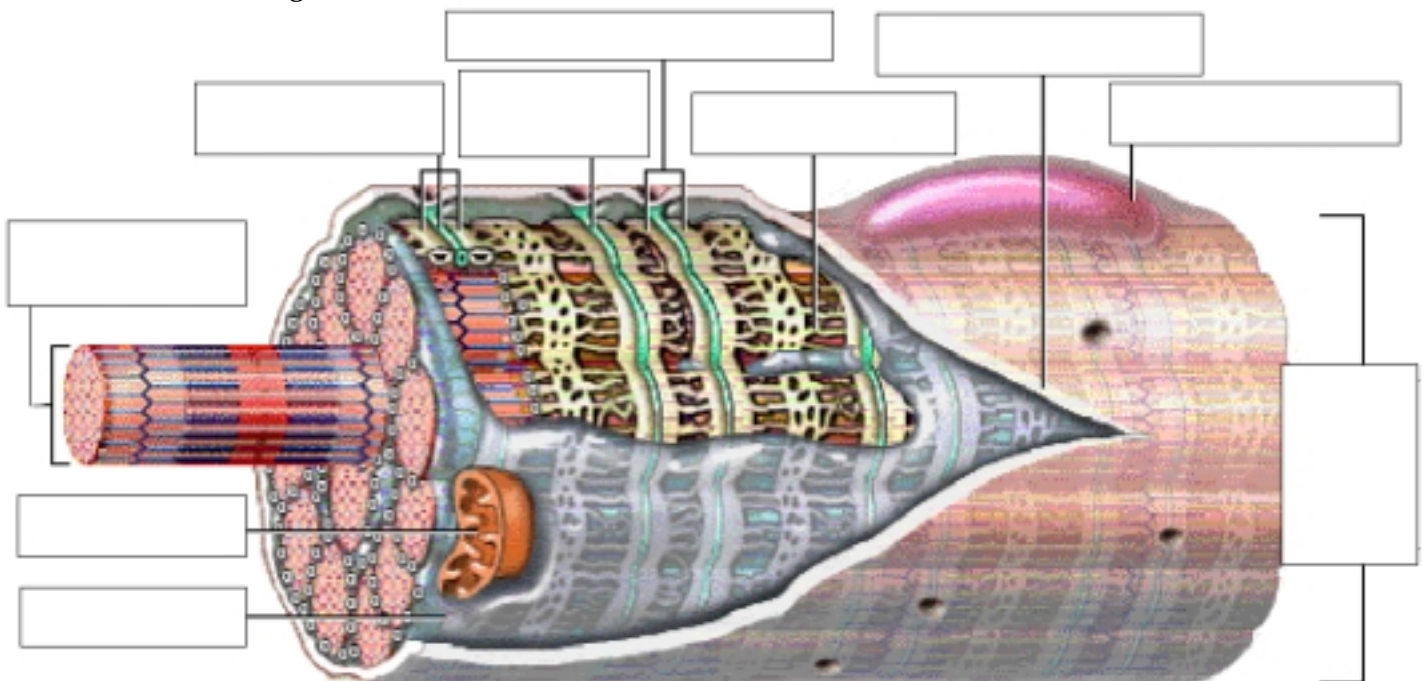
- Important Points About Endomysium:
 - Made of connective tissue.
 - Surrounds individual muscle cells.

- Functions to electrically insulates muscle cells from one another.
- Three connective tissue layers of the muscle (endomysium, perimysium, and epimysium):
 - Bind the muscle cells together.
 - Provide strength and support to the entire muscle.
 - Are continuous with the tendons at the ends of the muscle.
- Label this diagram:



Page 7. Internal Structure of a Skeletal Muscle Cell

- Label this diagram:



Muscle fibers: Alternative name for skeletal muscle cells.

- **Nucleus:** Contains the genetic material.
- **Sarcolemma:** Plasma membrane of the muscle cell.
- **Sarcoplasmic reticulum (SR):** Interconnecting tubules of endoplasmic reticulum that surround each myofibril.
- **Terminal cisternae:** Sac-like regions of the sarcoplasmic reticulum that contain calcium ions.
- **T tubules:** Invaginations of the sarcolemma that project deep into the cell.
- **Triad:** A group of one T tubule lying between two adjacent terminal cisternae.
- **Cytosol:** Intracellular fluid.
- **Mitochondria:** Sites of ATP synthesis.
- **Myofibril:** Contains the contractile filaments within the skeletal muscle cell.

** Now is a good time to go to quiz questions 2 and 3:

- Click the Quiz button on the left side of the screen.

- Click on the scrolling page list at the top of the screen and choose "2. Labeling Muscle Cell Structures".
- After answering question 3, click the Back to Topic button on the left side of the screen.
- To get back to where you left off, click on the scrolling page list at the top of the screen and choose "8. Structure of a Myofibril".

Page 8. Structure of a Myofibril

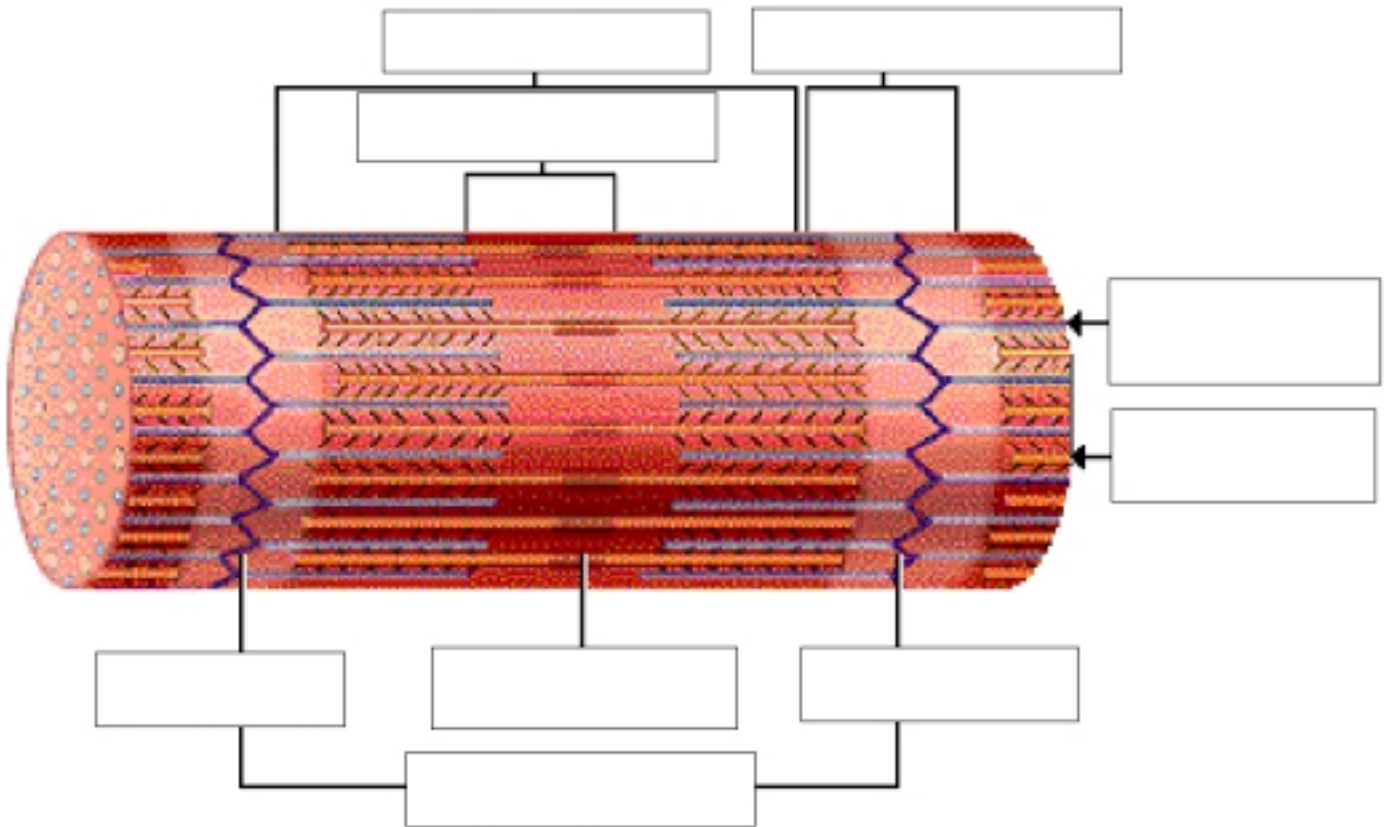
- Myofibrils: Contractile units within muscle cells.
 - Made of myofilaments called thin filaments and thick filaments.
 - Thin and thick filaments are made mainly of the proteins actin and myosin.

** Now is a good time to go to quiz question 4:

- Click the Quiz button on the left side of the screen.
- Click on the scrolling page list at the top of the screen and choose "4. Myofibril Puzzle".
- After answering question 4, click the Back to Topic button on the left side of the screen.
- To get back to where you left off, click on the scrolling page list at the top of the screen and choose "9. Arrangement of Myofilaments".

Page 9. Arrangement of Myofilaments

- Label the diagram:



- **A bands:** Dark areas that correspond to the areas where thick filaments are present.
- **I bands:** Light areas that contain only thin filaments.
- **Z line:** A protein disk within the I band that anchors the thin filaments and connects adjacent myofibrils.
- **H zone:** Located in the middle of each A band, this lighter stripe appears corresponding to the region between the thin filaments.
- **M line:** Protein fibers that connect neighboring thick filaments.
- **Sarcomere:** The region of the myofibril between two Z lines.

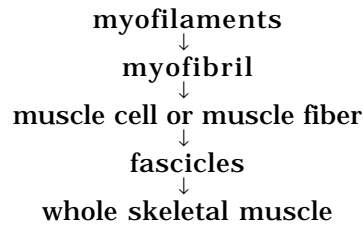
** Keep in mind, this information is crucial for your understanding of the sliding filament theory.

** Now is a good time to go to quiz question 5:

- Click the Quiz button on the left side of the screen.
- Click on the scrolling page list at the top of the screen and choose "5. Labeling a Myofibril".
- After answering question 5, click the Back to Topic button on the left side of the screen.
- To get back to where you left off, click on the scrolling page list at the top of the screen and choose "10. Review: Organizational Levels of Skeletal Muscle".

Page 10. Review: Organizational Levels of Skeletal Muscle

- "Bundle-within-a-bundle" organization of skeletal muscle:



Page 11. Pyramid of Subunits

- Whole muscle as a pyramid of subunits:
 - Fascicles
 - Muscle cells (Muscle Fibers)
 - Myofibrils
 - Myofilaments

Page 12. Summary

- The three types of muscle cells in the body are skeletal, cardiac, and smooth.
- Skeletal muscle has three layers of connective tissue: epimysium, perimysium, and endomysium.
- The striations of skeletal muscle cells are due to the organized arrangement of contractile proteins called thick and thin filaments.
- A whole muscle demonstrates a bundle-within-a-bundle organization:

myofilaments → myofibrils → muscle cells (muscle fibers) → fascicles → whole muscle

** Now is a good time to go to quiz question 6:

- Click the Quiz button on the left side of the screen.
- Click on the scrolling page list at the top of the screen and choose "6. Organizational Levels of Skeletal Muscle".

Notes on Quiz Questions:

Quiz Question #1: Three Types of Muscle Cells

- This question allows you to fill in a table which contains the characteristics of the various muscle cells.

Quiz Question #2: Labeling Muscle Cell Structures

- This question allows you to label the parts of a skeletal muscle cell.

Quiz Question #3: Definition of Muscle Cell Structures

- This question allows you to match the parts of the skeletal muscle cells to their definitions.

Quiz Question #4: Myofibril Puzzle

- This question allows you to assemble a myofibril.

Quiz Question #5: Labeling a Myofibril

- This question allows you to label the parts of a myofibril.

Quiz Question #6: Organizational Levels of Skeletal Muscle

- This question allows you to label the muscle at various levels of organization.

Study Questions on Anatomy Review: Skeletal Muscle Tissue

1. (Page 1.) What is the main function of skeletal muscles?
2. (Page 3.) List the three types of contractile cells of the body.
3. (Page 3.) Match the following types of contractile cells to their shape (branching, elongated, spindle-shaped):

- _____ a. Skeletal muscle cells
_____ b. Cardiac muscle cells
_____ c. Smooth muscle cells

4. (Page 3.) Match the following types of contractile cells to the characteristics of their nuclei and presence or absence of striations:

Cardiac Muscle Cells Smooth Muscle Cells Skeletal Muscle Cells

- _____ a. presence of visible striations & single, centrally-located nuclei
- _____ b. presence of visible striations & multiple peripheral nuclei
- _____ c. absence of visible striations & single, centrally-located nuclei
number of nuclei

5. (Page 4.) What is the name of the structure that attaches skeletal muscles to bones?

6. (Page 5.) Bundles of skeletal muscle cells are called _____.

7. (Page 5.) The connective tissue which immediately surrounds a muscle is called _____
and the connective tissue around the fascicles is called _____.

8. (Page 6.) What is the function of endomysium?

9. (Page 7.) Match these terms to their description:

- Triad
- T tubules
- Terminal cisternae
- Sarcolemma
- Muscle fibers
- Mitochondria
- Sarcoplasmic reticulum
- Myofibril

- _____ a. Sac-like regions of the sarcoplasmic reticulum that contain calcium ions.
- _____ b. Sites of ATP synthesis.
- _____ c. Plasma membrane of the muscle cell.
- _____ d. Alternative name for skeletal muscle cells.
- _____ e. Interconnecting tubules of endoplasmic reticulum that surround each myofibril.
- _____ f. A group of one T tubule lying between two adjacent terminal cisternae.
- _____ g. Invaginations of the sarcolemma that projecting deep into the cell.
- _____ h. Contains the contractile filaments within the skeletal muscle cell.

10. (Page 8.) What are the names for the two types of filament in a myofibril?

11. (Page 9.) What creates the skeletal muscle cell's striated appearance?

12. (Page 9.) Match the following:

A band I band H zone

- _____ a. Contains only thin filaments.
- _____ b. Contains only thick filaments.
- _____ c. Contains both thin and thick filaments.

13. (Page 9.) Perpendicular to the myofilaments are the Z lines and the M lines. The Z lines connect the _____ filaments and the M lines connect the _____ filaments.
14. (Page 9.) The region of the myofibril between two Z lines that is the contractile unit of a muscle cell is called a _____ .
15. (Page 10.) Arrange the following from smallest structure to largest structure:
 Muscle cell or muscle fiber
 Fascicle
 Myofilaments
 Whole skeletal muscle
 Myofibril

Answers to Questions on Anatomy Review: Skeletal Muscle Tissue

1. Movement of the body.
2. Skeletal muscle cells, cardiac muscle cells, and smooth muscle cells.
3. a. elongated b. branching c. spindle-shaped
4. a. Cardiac Muscle Cells b. Skeletal Muscle Cells c. Smooth Muscle Cells
5. Tendons
6. Fascicles
7. Epimysium, perimysium
8. Electrically insulates muscle cells from one another.
9. a. Terminal cisternae
 b. Mitochondria
 c. Sarcolemma
 d. Muscle fibers
 e. Sarcoplasmic reticulum
 f. Triad
 g. T tubules
 h. Myofibril
10. Thin filaments and thick filaments.
11. The arrangement of thick and thin myofilaments, which form light and dark alternating bands.
12. A band: c I band: a H zone: b
13. Thin, thick
14. Sarcomere
15. Myofilaments, Myofibril, Muscle cell or muscle fiber, Fascicle, Whole skeletal muscle